

PATIENT

Pico Brooker

SPECIES

Canine

BREED

Chihuahua

SEX

Intact Male

AGE

16½ years

WEIGHT

8 #

INTERPRETED BY

Remo Lobetti, BVSc,
MMedVet (Med),
PhD, Dipl. ECVIM

IMAGING PERFORMED BY

Lara Wiseman, DVM

HOSPITAL NAME

Village Royale Animal
Clinic

REFERRING VET

INVOICE

303110

DATE

7/8/22

PRESENTING CLINICAL SIGNS

History: Lethargy.

Physical Examination: N/A.

Urinalysis: N/A.

CBC: N/A.

Serum Biochemistry: Elevated liver enzyme activity and bilirubin.

Radiographic Findings: N/A.

ULTRASONOGRAPHIC EXAMINATION OF THE ABDOMEN

Urinary System

Full urinary bladder with a normal thickness and echogenic appearance of the wall. Small amount of floating hyperechogenic sediment. No uroliths evident.

Normal trigone area, proximal urethra (0.2 cm), and iliac blood vessels.

Normal iliac lymph nodes. Ureters not visualized.

Normal renal size (left 4 cm), hyperechogenic appearance, some loss of cortico-medullary differentiation, and pelvis, and capsule. Bilateral mild pelvic mineralization.

Reproductive System

Prostamegaly (2.1 cm) with a diffuse increased echogenic appearance. Hyperechogenic nodule (1.1 x 1.6 cm) in the left testicle.

Adrenal Glands

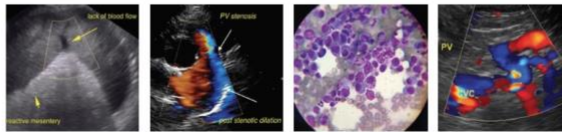
Normal shape, echogenic appearance, position, and size. Left 0.55 cm, right 0.41 cm.

Spleen

Normal size (1 cm) and echogenic appearance. Smooth homogenous parenchyma, smooth curvi-linear capsule, and normal vasculature. No evidence of inflammatory, neoplastic, infarction, or infiltrative changes noted.

Liver

Normal size with a diffuse increased echogenic appearance and some loss of portal markings. Focal parenchymal hyperechoic nodule in the left liver lobe (1 cm). No nodules or masses evident. Full gall bladder containing normal anechoic bile. Irregular poorly vascularized mass within the lumen of the gallbladder. Normal thickness and appearance of the gall bladder wall. Normal bile duct (0.3 cm).



PATIENT

Pico Brooker

SPECIES

Canine

BREED

Chihuahua

SEX

Intact Male

AGE

16½ years

WEIGHT

8 #

INTERPRETED BY

Remo Lobetti, BVSc,
MMedVet (Med),
PhD, Dipl. ECVIM

IMAGING PERFORMED BY

Lara Wiseman, DVM

HOSPITAL NAME

Village Royale Animal
Clinic

REFERRING VET

INVOICE

303110

DATE

7/8/22

Gastrointestinal

Normal appearance of the stomach, duodenum, small intestine, ileo-cecal junction, and colon with no loss of layering, normal wall thickness (duodenum 0.43 cm, jejunum 0.3 cm) and peristaltic activity, and no distension of the lumen.

Pancreas

Normal size (0.8 cm) and echogenic appearance. Regular capsule. Normal echogenic appearance of the mesentery and fat surrounding the pancreas.

Free Abdomen

Normal mesenteric lymph nodes.

Enlarged hepatic lymph nodes (1.8 cm) with a rounded shape and increased echogenic appearance.

No ascites.

ULTRASONOGRAPHIC FINDINGS

Primary findings:

- Gall bladder mass.
- Hepatopathy.
- Hepatic nodule.
- Hepatic lymphadenomegaly.

Secondary findings:

- Urinary bladder sediment.
- Testicle nodule.
- Benign prostatic hyperplasia.

INTERPRETATION OF THE FINDINGS & FURTHER RECOMMENDATIONS

The most likely etiology for the gallbladder mass would be neoplasia but as the gallbladder is not distended does not appear to be causing an obstruction.

Etiologies for the hepatopathy would be reactive, hyperplasia, vacuolar, metabolic, chronic hepatitis, early cirrhosis, early nodular regeneration, with infiltrative neoplasia, a far less likely differential diagnosis

The hepatic nodule is most likely and incidental finding.

The most likely etiology for the hepatic lymph node would be reactive with lymphadenitis and infiltrative neoplasia, less likely differential diagnoses.

Further assessment that could be considered would be urinalysis and FNA cytology of the liver.

Specific therapy would be dependent on an etiological diagnosis. Symptomatic management would be castration and ursodiol.



PATIENT

Pico Brooker

SPECIES

Canine

BREED

Chihuahua

SEX

Intact Male

AGE

16½ years

WEIGHT

8 #

INTERPRETED BY

Remo Lobetti, BVSc,
 MMedVet (Med),
 PhD, Dipl. ECVIM

IMAGING PERFORMED BY

Lara Wiseman, DVM

HOSPITAL NAME

Village Royale Animal
 Clinic

REFERRING VET

INVOICE

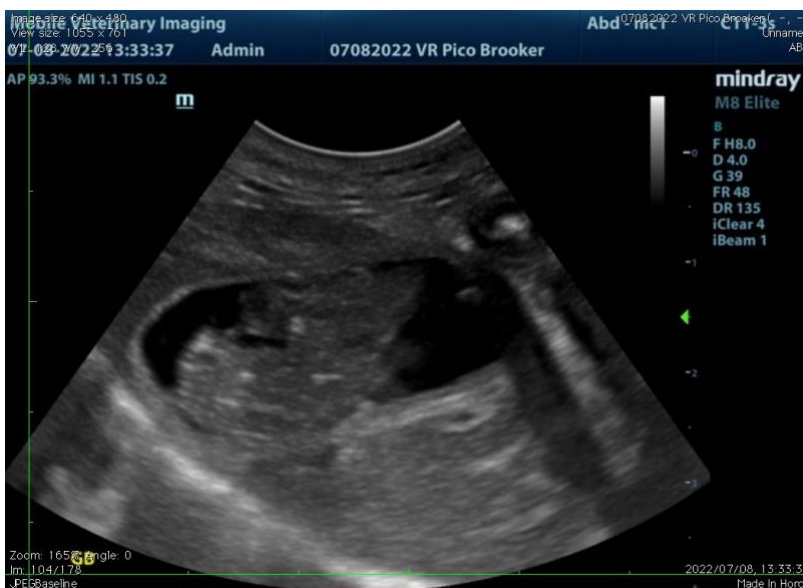303110

DATE

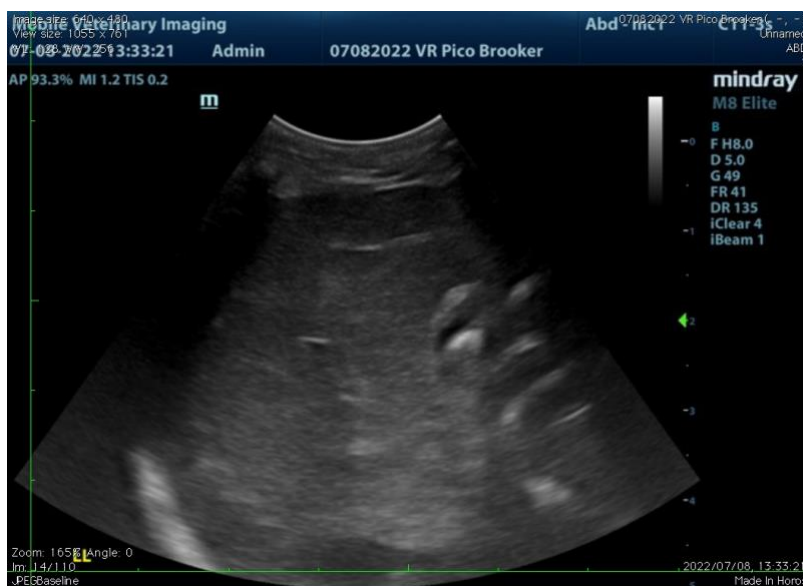7/8/22

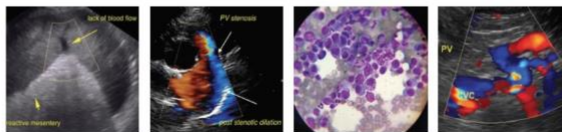
IMAGES

Gall bladder



Liver





PATIENT

Pico Brooker

SPECIES

Canine

BREED

Chihuahua

SEX

Intact Male

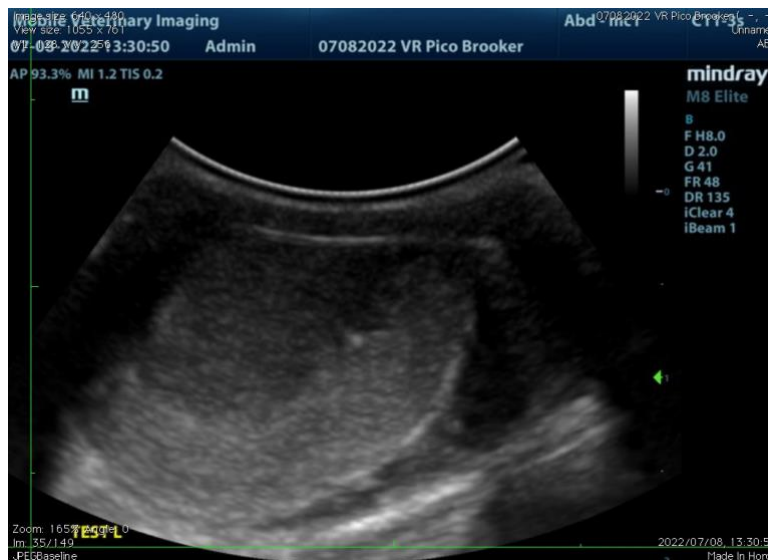AGE

16½ years

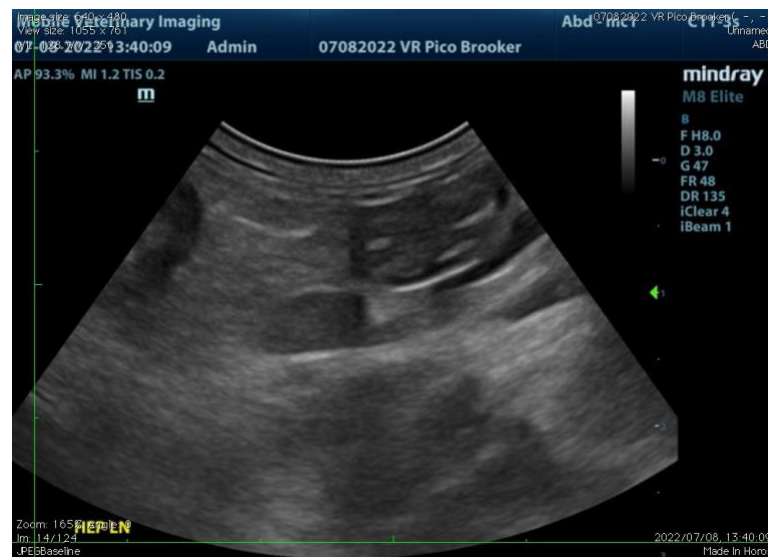WEIGHT

8 #

Left testes



Hepatic lymph node



INTERPRETED BY

Remo Lobetti, BVSc,
MMedVet (Med),
PhD, Dipl. ECVIM

IMAGING PERFORMED BY

Lara Wiseman, DVM

HOSPITAL NAME

Village Royale Animal
Clinic

REFERRING VET

INVOICE

303110

DATE

7/8/22

The information and recommendations provided are based on the images presented by the referring veterinarian. No evaluation can be communicated regarding pathology that was not visible in the image/video clips provided.

Thank you for this referral. If the clinical or image interpretation does not parallel your findings or if I can be of any further assistance please contact me.

Remo Lobetti, BVSc, MMedVet (Med), PhD, Dipl. ECVIM (Internal Medicine)
rlobetti@mweb.co.za